

CORRECTION

Open Access



Correction: Oblique lateral internal fusion combined with percutaneous pedicle screw fixation in severe lumbar spinal stenosis: clinical and radiographic outcome

Chen Liu^{1,2,3}, Yin Geng^{1,2} and Yifeng Li^{1,2*}

Correction: Journal of Orthopaedic Surgery and Research (2023) 18:882
<https://doi.org/10.1186/s13018-023-04373-5>

Following publication of the original article [1], the authors identified an error in Fig. 1. The correct figure is given below.

The original article [1] has been revised.

Published online: 11 December 2023

The original article can be found online at <https://doi.org/10.1186/s13018-023-04373-5>.

*Correspondence:

Yifeng Li
lyf_0209@126.com

¹ Department of Spine Surgery, First Affiliated Hospital of Wannan Medical College, No. 2 Zheshan West Road, Wuhu 241001, Anhui, China

² Spine Research Center of Wannan Medical College, No. 22 Wenchang West Road, Wuhu 241001, Anhui, China

³ Key Laboratory of Non-Coding RNA Transformation Research of Anhui Higher Education Institution, Wannan Medical College, Wuhu 241001, Anhui, China

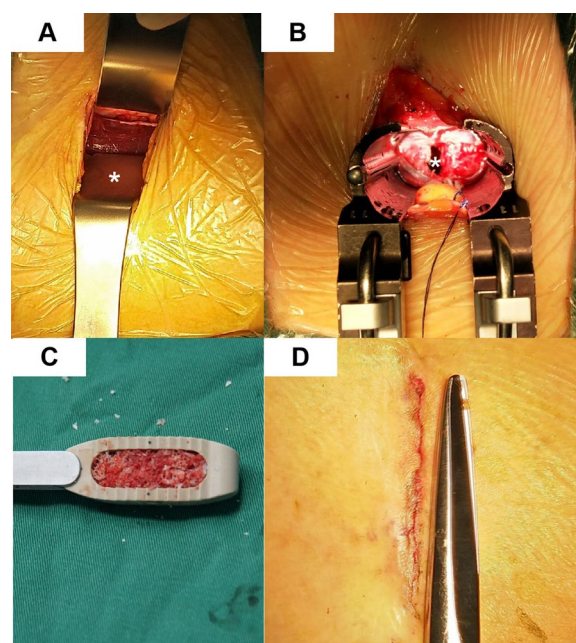


Fig. 1 OLIF surgery procedure. **A** The psoas muscle was exposed (*, psoas major muscle). **B** The operative space was dilated with the retractors (*, intervertebral disc space). **C** The huge OLIF cage is filled with allografts. **D** The postoperative incision



Publisher's Note

Springer Nature remains neutral with regard to jurisdictional claims in published maps and institutional affiliations.